

# Digital Workflow for Full-Arch Implant-Supported Prosthesis Based on Intraoral Scans of a Relative of the Patient

Alexandre Domingues Teixeira Neto, DDS, MS<sup>1</sup>

Alan Jony de Moura e Costa, DDS<sup>1</sup>

Isabela Goulart Gil Choi, DDS, MS<sup>2</sup>

Alexandre Santos, CDT<sup>3</sup>

Julio Fernando dos Santos, CDT<sup>3</sup>

Arthur Rodriguez Gonzalez Cortes, DDS, PhD<sup>4\*</sup>

## INTRODUCTION

Digital workflow has revolutionized the field of dentistry. In addition to digital radiographs and photographs, a 3-dimensional (3D) virtual patient can be created for diagnosing and simulating an entire treatment plan noninvasively. Furthermore, digital workflow allows for sharing treatment plan data immediately with other professionals via network-communication tools. These, in turn, help to achieve patient expectations.<sup>1</sup>

When combined with intra- and extraoral scanners, facial analyses such as digital smile design are significant beneficial to the esthetic demands of the patient.<sup>2</sup> Moreover, combination and integration of all data from hard (cone-beam computerized tomography [CBCT]) and soft tissues (intra- and extraoral scans) to be used during virtual surgical and prosthetic planning enable an even better prediction of treatment outcomes. Among the advantages of the aforementioned methodology are the virtual wax-up tools for easy adjustments of teeth, shape, size, and position, as well as occlusal modifications according to the patient's morphological features and conditions.<sup>3,4</sup> However, selecting tooth shapes from a variety of digital libraries may be time-consuming to achieve patients' expectations.

Different methodologies for assessing the esthetic characteristics of patients have been proposed in the literature. One of the available methods is the use of an application named "digital smile design" (DSD), which allows for previsualization of esthetic outcomes during prosthetic treatment planning.<sup>5</sup> The rationale of using DSD in implant dentistry is to conduct facially driven surgical and prosthetic planning, as well as decision

making with regard to treatment choices for the patient. However, little is known about the impact of DSD on digital workflows for full-arch implant-supported prostheses.

Thus, the aim of this report is to describe a digital workflow for maxillary full-arch implant rehabilitation based on dental arch characteristics of a relative of the patient to be rehabilitated, as desired by the own patient. The patients involved in the performed dental technique signed an informed consent form giving permission for publication of this technical/clinical case.

## CASE REPORT

A 58-year-old female patient presented at the clinic of the university of this study. She was using a full-arch implant-supported temporary prosthesis and was dissatisfied with the respective esthetics (Figure 1a and b). Initially, we scanned both primary and antagonist arches as well as the occlusion of the patient using an intraoral scanner (Trios II, 3Shape, Copenhagen, Denmark). The temporary prosthesis was removed, and all implants (Neodent, Curitiba, Brazil) were scanned with the same intraoral scanner using scan bodies for screw-retained abutments (Mini Pilar, 4.1 mm in diameter, Neodent; Figure 2a). Then, to complete occlusal registration, we split the temporary prosthesis at the sagittal midline with a cylindrical drill and again scanned the primary arch with half of the provisional prosthesis in position and without scan bodies in the opposite side to scan soft tissues around the screw-retained abutments. Finally, another intraoral scan was performed again after switching the side of the half temporary prosthesis. All obtained images were saved in standard tessellation language (STL) file format.

All resulting STL files were imported in the same computer-aided design (CAD) software (Meshmixer, Autodesk, San Rafael, Calif). We created both maxillary and mandibular digital casts with slots designed for conventional implant analogs at the primary arch and connected the casts with a bar. Then, we printed 3-dimensionally (Titan II, Kudo3d, Pleasanton, Calif) both casts and artificial gingiva of the primary arch using cast

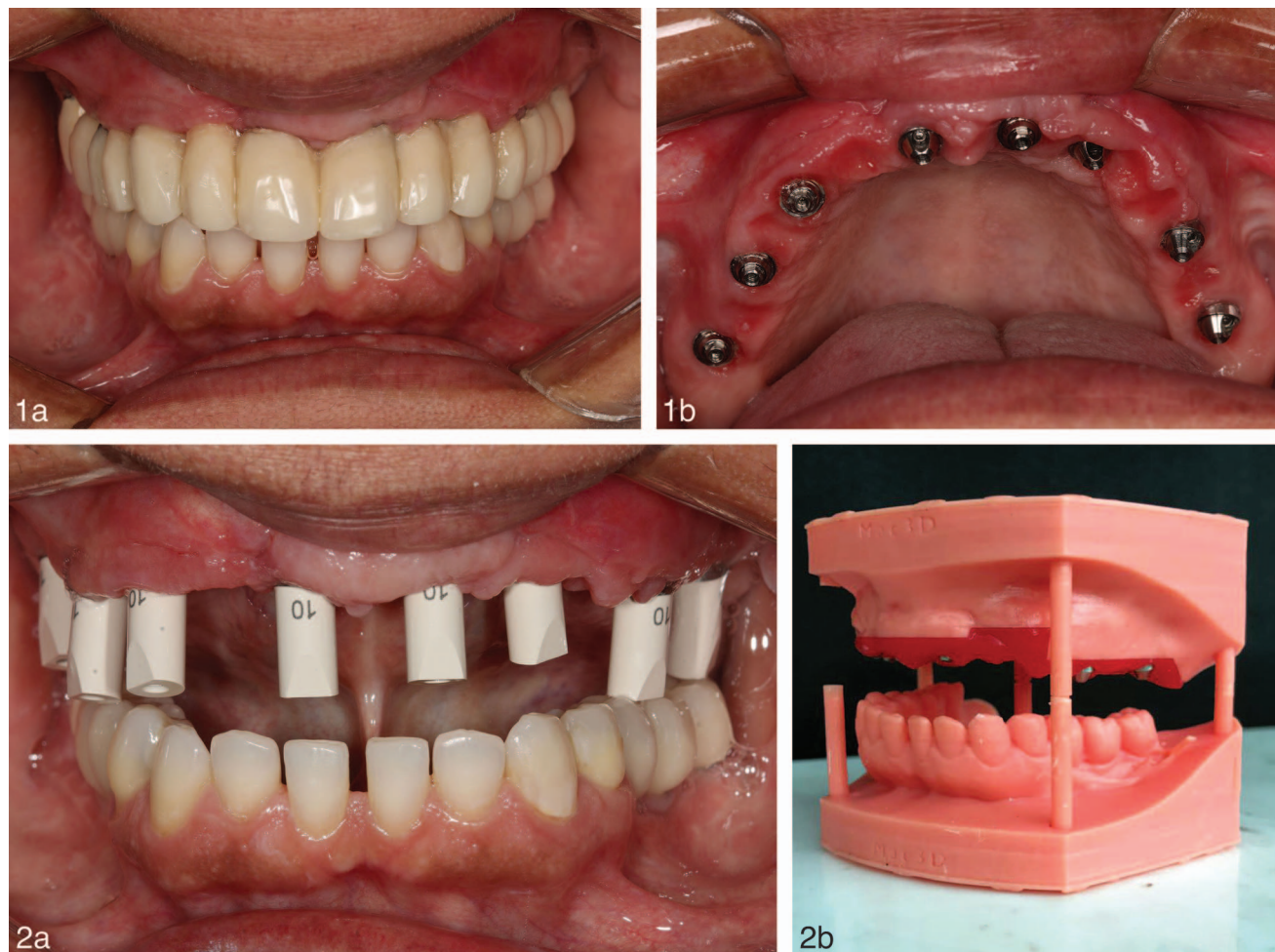
<sup>1</sup> Private practice, Department of Implant Dentistry, GoBeyond Institution, Curitiba, Brazil.

<sup>2</sup> Department of Oral Radiology, School of Dentistry, University of São Paulo (USP), São Paulo-SP, Brazil.

<sup>3</sup> Private practice, Department of Prosthodontics, Studio Art Dental, Curitiba, PR, Brazil.

<sup>4</sup> Department of Dental Surgery, Faculty of Dental Surgery, University of Malta, Msida, Malta.

\* Corresponding author, e-mail: arthur.nogueira@um.edu.mt  
<https://doi.org/https://doi.org/10.1563/aaid-joi-D-20-00095>



**FIGURES 1 AND 2.** **FIGURE 1.** (a) Initial clinical view of the full-arch implant-supported temporary prosthesis. (b) Initial occlusal view of the abutments without the temporary prosthesis. **FIGURE 2.** (a) Without the temporary prosthesis and using scan bodies for screw-retained abutments for digital scanning of maxillary implants. (b) Maxillary/mandibular casts and artificial gingiva printed 3-dimensionally using resins. Both casts are connected with a bar.

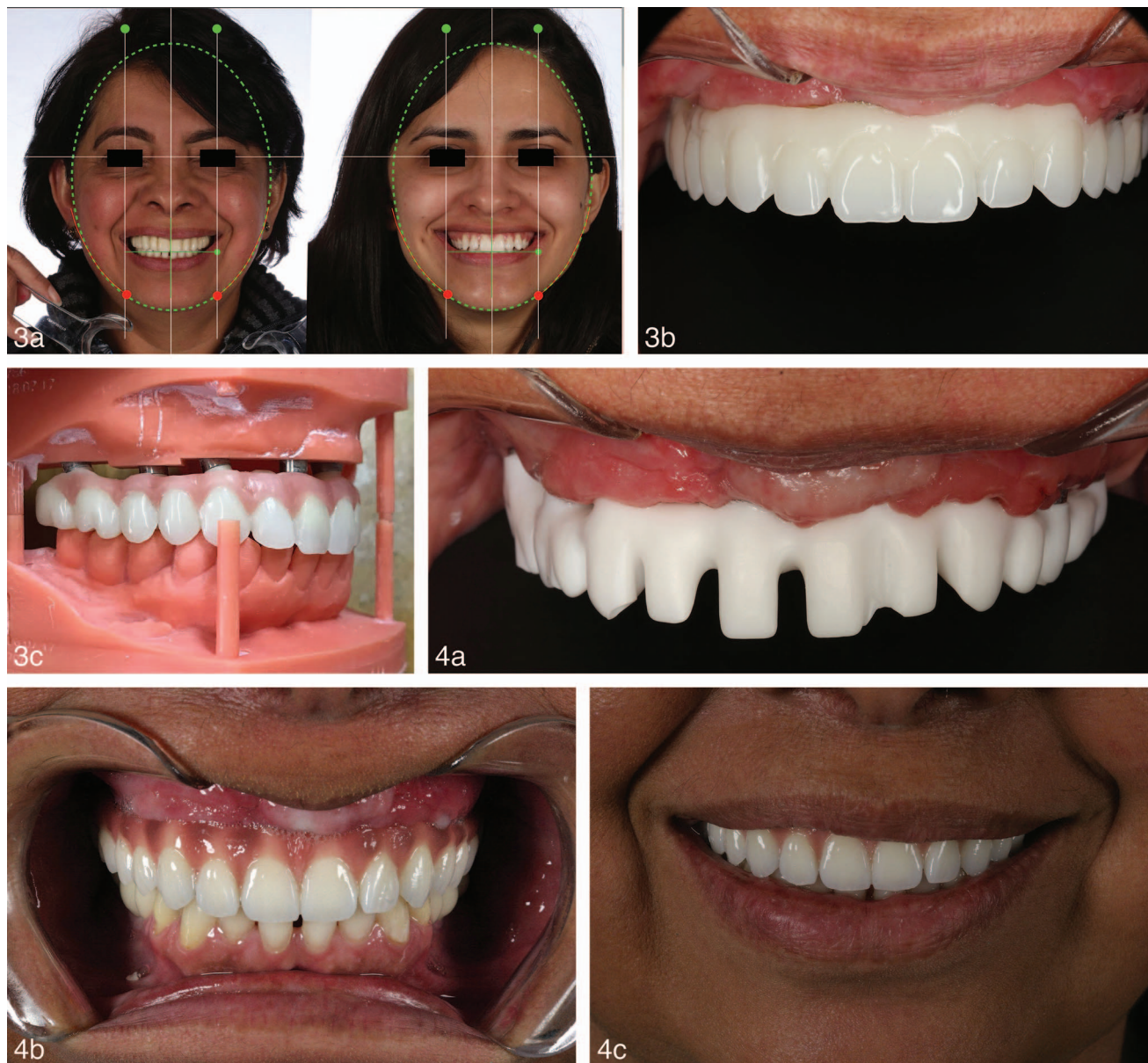and soft resins (Makertech Labs, Curitiba, Brazil), respectively (Figure 2b).

The patient selected the dental arch shape and smile of her daughter as a base for her full-arch implant-supported prosthesis. We performed facial analysis with the DSD methodology to confirm whether both patient and her daughter had similar esthetic characteristics (Figure 3a). The patient's daughter underwent an intraoral scan of the maxillary dental arch. The resulting image was exported as an STL file, and the digital design of the teeth was edited to adjust to the main patient's esthetics. Then, we digitally designed (Modellier Software, Zirkonzahn, Gais, Italy) and fabricated a temporary polymethyl methacrylate (PMMA, Trilux Multilayer, RuthiBras, Pirassununga, Brazil) prosthesis from the resulting STL file with a milling machine (Zirkonzahn M4, Zirkonzahn; Figure 3b). The resulting temporary PMMA prosthesis was screwed in the implant analogues of the 3D-printed casts to check occlusion and to make occlusal adjustments (Figure 3c). We tried the temporary prosthesis in the oral cavity and made a silicone mask to assist in the layered application of ceramic to be made afterward.

Considering the STL file of the temporary PMMA prosthesis, we digitally designed (Modellier Software) and milled (Zirkonzahn M5) a compatible zirconia framework (Figure 4a). Then, we performed a layered application of gingival and tooth-colored ceramic (Creation CC, Creation Willi Geller International GmbH, Meiningen, Austria) over the zirconia framework by using the previously made 3D-printed casts and silicone mask to finish the definitive full-arch implant-supported prosthesis (Figure 4b and c).

#### DISCUSSION

The present dental technique is aimed to offer more options to achieve fast satisfactory esthetic outcomes with an implant digital workflow, without using digital libraries. In this context, the rehabilitation of one patient's dental arch based on the intraoral scan of a second patient requires both patients to have similar facial measurements. After superimposing the intraoral scans of both patients in the CAD software, the professional can digitally edit the teeth shape, color, and occlusion to match the clinical situation of the patient receiving implant rehabilitation.<sup>3,6</sup>



**FIGURES 3 AND 4. FIGURE 3.** (a) The patient selected the dental arch shape and smile of her daughter as a base for her full-arch implant-supported prosthesis. The facial analysis of digital smile design methodology can be then used to confirm whether patients and relatives have similar esthetic characteristics. (b) Provisional polymethyl methacrylate (PMMA) fabricated from the digital design of the teeth adjusted to the main patient's esthetics. (c) PMMA prosthesis screwed in the implant analogues of the 3-dimensionally-printed casts to check occlusion and make occlusal adjustments. **FIGURE 4.** (a) Considering the final standard tessellation language file, a compatible zirconia framework was digitally designed and milled. (b) Final maxillary prosthesis with layered application of gingival and tooth-colored ceramic over the zirconia framework. (c) Patient's final natural smile.

The present findings are in agreement with a previous study on digital workflow for full-arch implant rehabilitation using a similar methodology for digital prosthetic planning.<sup>7</sup>

Among the main advantages of a digital workflow compared with conventional procedures are fewer patient visits, better results of marginal fit, and reproducibility of the prosthesis.<sup>6</sup> Furthermore, despite the fact that the case report described herein involved the rehabilitation of osseointegrated implants, the present digital workflow can also be used for treatment planning before implant placement (ie, for surgical

planning of image-guided implant surgeries). For this purpose, facial and intraoral scans should be used for performing digital prosthetic planning, before combination with CBCT scans. As a result, prosthetically driven implant planning and the corresponding surgical guide design can be performed with satisfactory precision,<sup>7</sup> even if bone grafts are required before implant placement.<sup>8,9</sup>

The main disadvantage of the present methodology was to achieve an appropriate occlusal registration, which is expected for digital workflows in full-arch implant rehabilitations.<sup>2</sup> As a

result, 2 intraoral scans were necessary to register the patient's occlusion. For this purpose, however, the provisional prosthesis had to be split at the sagittal midline and scanned one-half at a time without scan bodies in the opposite side, to achieve an appropriate vertical dimension while capturing images of soft-tissue conditions around implant abutments.

In conclusion, the present technique allows for a full digital workflow for maxillary full-arch implant rehabilitation based on intraoral scans of a relative of the patient who had similar esthetic characteristics.

#### ABBREVIATIONS

3D: 3 dimensional  
CAD: computer-aided design  
CBCT: cone-beam computerized tomography  
DSD: digital smile design  
PMMA: polymethyl methacrylate  
STL: standard tessellation language

#### NOTE

The authors declare they have no conflicts of interest related to this study. No funding was provided for this study.

#### REFERENCES

1. Joda T, Gallucci GO. The virtual patient in dental medicine. *Clin Oral Implants Res.* 2015;26:725–726.
2. Mangano C, Luongo F, Migliario M, Mortellaro C, Mangano FG. Combining intraoral scans, cone beam computed tomography and face scans: the virtual patient. *J Craniofac Surg.* 2018;29:2241–2246.
3. Hassan B, Greven M, Wismeijer D. Integrating 3D facial scanning in a digital workflow to CAD/CAM design and fabricate complete dentures for immediate total mouth rehabilitation. *J Adv Prosthodont.* 2017;9:381–386.
4. Zhao YJ, Xiong YX, Wang Y. Three-dimensional accuracy of facial scan for facial deformities in clinics: a new evaluation method for facial scanner accuracy. *PLoS One.* 2017;12:e0169402.
5. Coachman C, Georg R, Bohner L, Rigo LC, Sesma N. Chairside 3D digital design and trial restoration workflow. *J Prosthet Dent.* 2020;124:514–520.
6. Bidra AS, Taylor TD, Agar JR. Computer-aided technology for fabricating complete dentures: systematic review of historical background, current status, and future perspectives. *J Prosthet Dent.* 2013;109:361–366.
7. Costa AJM, Teixeira Neto AD, Burgoa S, Gutierrez V, Cortes ARG. Fully digital workflow with magnetically connected guides for full-arch implant rehabilitation following guided alveolar ridge reduction. *J Prosthodont.* 2020;29:272–276.
8. Pinhata-Baptista OH, Gonçalves RN, Gialain IO, Cavalcanti MGP, Tateno RY, Cortes ARG. Three dimensionally printed surgical guides for removing fixation screws from onlay bone grafts in flapless implant surgeries. *J Prosthet Dent.* 2020;123:791–794.
9. Gialain IO, Pinhata-Baptista OH, Cavalcanti MGP, Cortes ARG. Computer-aided design/computer-aided manufacturing milling of allogeneic blocks following three-dimensional maxillofacial graft planning. *J Craniofac Surg.* 2019;30:e413–e415.

Queries for orim-46-06-09

This article has been edited and typeset from the submitted materials. Please check proofs carefully for accuracy and follow the [Allen Press Guide to PDF Annotation](#) when marking revisions. Do not edit the PDF directly.

If present, queries will be listed below with corresponding numbers in the margins or may appear as PDF comments addressed to the author or editor. If a correction is desired in response to a query, mark the necessary changes directly in the proof using the appropriate annotation tool. If no change is desired, please highlight the query number in the margins and mark “No change needed” or reply to the PDF annotation with “No change needed”.